

Modern Military Neurotrauma and its Complications in War Conditions in megalopolis

Lystratenko OI¹, Kardash AM² and Lystratenko DO³

¹Department of Neurosurgery, Donetsk National University, Neurosurgical clinic, Ukraine

²Department of Neurosurgery, Donetsk National Medical University, DoKTMO, Ukraine

³Department of Neurosurgery, Donetsk Intern in Neurosurgical clinic, Ukraine

Volume 2 Issue 1- 2019

Received Date: 01 Feb 2019

Accepted Date: 21 Feb 2019

Published Date: 25 Feb 2019

2. Keywords

Battle trauma; War in megalopolis; The organization of neurosurgical care; Treatment; Surgical rehabilitation

1. Abstract

This work contains information about military neurosurgical traumas with their complications. Here will be spoken about neurosurgical medical treatment in the present military actions (local military conflict in Don bass from 2014 till nowadays). You can realize what kind of neurosurgical treatment could be used in megalopolis which appears under fire. Content of the work: soft tissue-damages, open not penetrating wounds, open penetrating wounds with- and without- brain perforation (**Figure 1,2 and 3**). In addition will be noticed the difference between projectile (shrapnel) wounds and bullet wounds with their following treatment based on numerous cases of such kind of injuries. This work has some pictures in order to show pre- and post- operative patient's condition (**Figure 4,5,6.7 and 8**)

(Figure1-3): Group of patients is the most numerous. PST was provided in the next few hours from the moment of injury. Patients with concussion of brain were treated in the clinic of neurosurgery for a short time - up to 10 days. The prognosis for life is favorable.

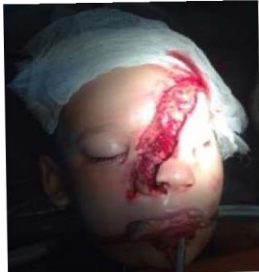

Figure 1

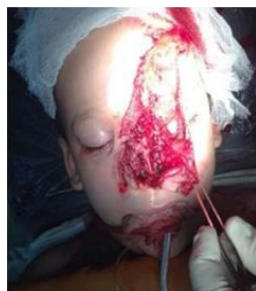

Figure 2

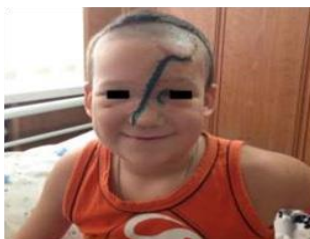

Figure 3

(Figure 4-8) : Patient group - Characterized by a more severe course of head injury. Operations were carried out to remove bone fragments and shell fragments. Extensive skin defects were replaced with autografts. The plastic of extensive skin defects was carried out together with the combustiologists, as an urgent operation to prevent pyoinflammatory complications of the central nervous system. Duration of stay of patients is up to 2 months, including several stages - such patients underwent reconstructive operations. The prognosis for life is favorable.

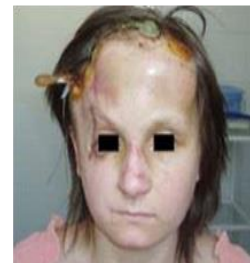

Figure 4: Reconstructive operation with implantation of end expander

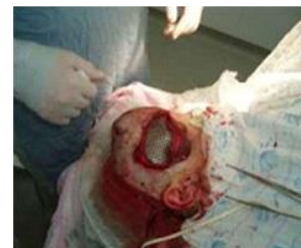

Figure 5

*Corresponding Author (s): Jaideep Kumar Trivedi, Department of Cardio Thoracic and Vascular Surgery, Apollo Vishakhapatnam, India, E-mail: drjdrivedi@yahoo.co.in

Citation: Lystratenko OI, Kardash AM and Lystratenko DO, Modern Military Neurotrauma and its Complications in War Conditions in megalopolis. Annals of Clinical and Medical Case Reports. 2019; 2(1): 1-4.

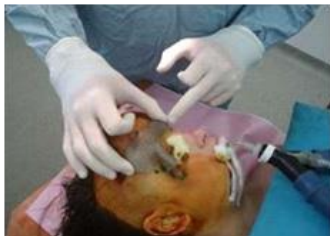

Figure 6

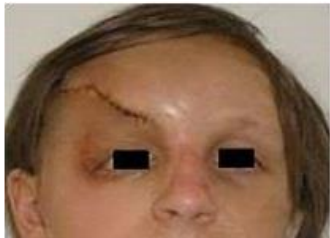

Figure 7

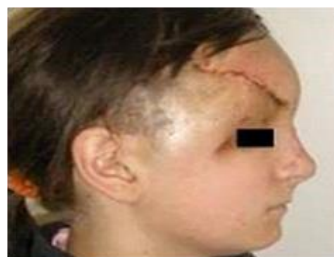

Figure 8

3. Materials and Methods

Over the period from May 2014 to the present in the neurosurgery clinic more than 4000 people with closed and open (penetrating) head injuries (which were received during the military actions) was given appropriate neurosurgical care. Patients were examined with CT, MRI, radiography of the skull bones [1].

The patients were examined by traumatologists, ENT specialists, oculists, maxillofacial surgeons, combustiologists, neuroreanimatologists. Time from injury to operation is up to 2 hours (Figure 18,19,20,21 and 22). The military actions are taking place in a megapolis (in a city with a population of 1 million inhabitants). The distance from the closest flashpoint till the neurosurgical clinic is approximately 13 km (Figure 23, 24 and 25). The patients underwent neurosurgical operations - primary surgical treatment (PST) of gunshot wounds of the skull with the removal of hematomas, bone fragments and shell fragments, plastic of bone defects, skull surfaces [2].

(Figure 9 – 17): The group of patients - The most severe category of patients is the group of patients with severe brain damage. Lethal outcome is up to 15% high degree of disability. As a result - a long period of rehabilitation and social adaptation - up to 8 months. Bullet open penetrating wound of brain

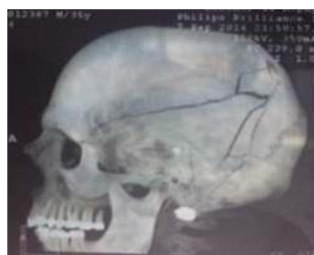

Figure 9: Bullet stopped near C1

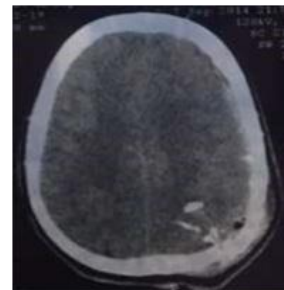


Figure 10

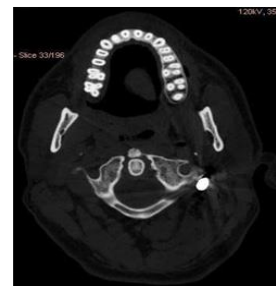

Figure 11

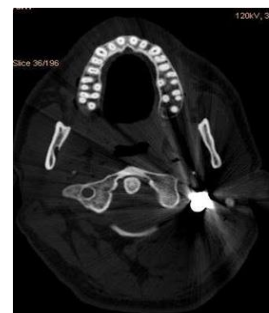

Figure 12

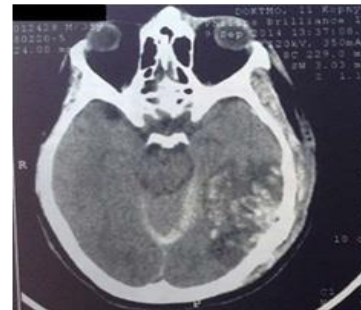


Figure 13: Postoperative photos

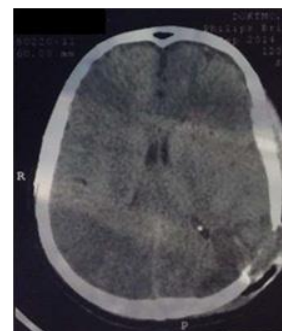


Figure 14

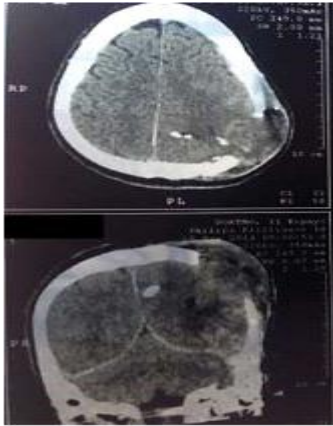

Figure 15: Fungus

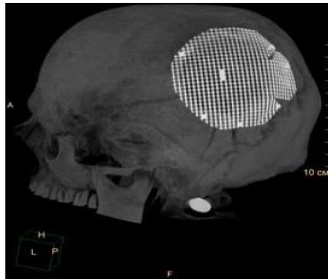


Figure 16: Plastic of defect after 7 month



Figure 17: 7 month after operation

(Figure 18 - 22): Projectile open penetrating wound of brain

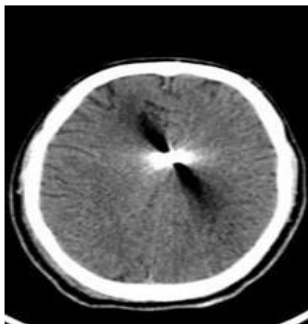


Figure 18: Projectile wound above the corpus callosum

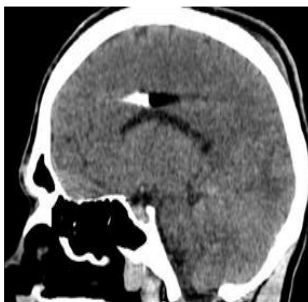

Figure 19

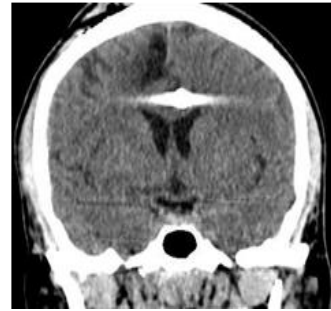


Figure 20

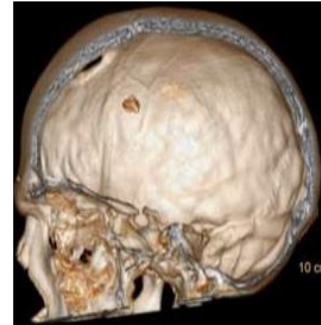

Figure 21

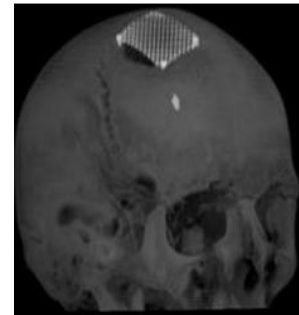


Figure 22

(Figure 23-25): This is a patient with an open penetrating projectile wound of the skull with a huge brain affection in occipital, left temporal regions. The patient was operated on. But prognosis is unfavorable due to huge brain affection with a lot of projectiles.

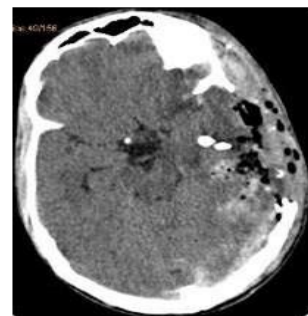


Figure 23

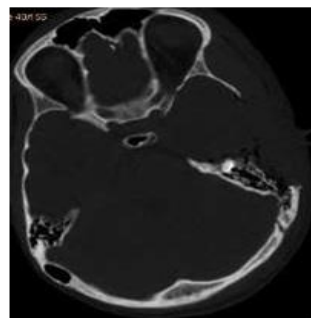


Figure 24

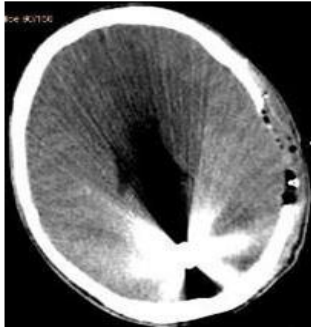

Figure 25

4. Results

Wounds of soft tissues of the skull are up to 2000 people. Non-penetrating wounds of the skull bones are up to 1200 people. Penetrating craniocerebral injuries are up to 800 people [3 - 6].

5. Conclusion

By modern military actions in a megalopolis conditions more than 50% of the injured are injured in the head. In military operations in addition to soldiers among the victims are a large number of civilians - up to 25%. During military actions in the megalopolis, the first medical aid was provided by ambulance teams, which delivered patients to the clinic of neurosurgery. The military first medical aid was given on the battlefield [6]. These patients were delivered by passing transport. Time from getting the wound to providing specialized neurosurgical care to all patients is up to 2 hours. In connection with this the number of pyoinflammatory complications after treatment of patients with gunshot wounds to the skull is relative small - up to 1%. Died patients were in up to 20% of cases had combined wounds of the limbs, chest, abdomen, head.

So we determined that:

- The average time from admission of a patient till getting professional neurosurgical care should be not more than 2 hours.
- The number of pyoinflammatory infections by projectile wounds of the skull directly depend on the speed of receiving professional neurosurgical treatment.
- The projectiles with depth localization are not recommended to remove.

- Prognosis of life of patient damaged with projectile is higher, in comparison with damaged with bullet because of low kinetic force of projectile.

- By bullet wounds are taking place more tissue damages due-to higher kinetic force of bullet.

- Primary surgical treatment (PST) is performed outside the specialized center only because of vital indications to non-transportable patients. Transportable patients should be transported as quicker as possible in a specialized neurosurgical center in order to reduce the liquorrhea, tissue, vascular and pyoinflammatory complications.

Reference

1. Okie S. Traumatic brain injury in war zone/ S.Okie//New Engl. J.Med.-2005; Vol. 352: N20 P. 2043 - 47.
2. B.V.Gaidar, U.A.Shulev, U.V.Dikarev// Battle injuries of skull and brain/ Practical neurosurgery: guidelines for doctors under red. B.V.Gaidar – СПб.:Гиппократ, 2002; P.112 - 136.
3. Gean A.D. Brain injury: applications from war and terrorism/ Philadelphia: Lippincott Williams & Wilkins, 2014; -338p.
4. Beseri, ND, Santel J, Jelavic Koic. CT analysis of missile head injury// Neuroradiology. 1995; Vol.37 N3: P. 207 - 211.
5. Clinical practice guidelines. Joint theater trauma system: practical emergency information for critical trauma care from military experts/ United States Army, Department of Defense, Medical Research and Materiel Command, United States Military, United States Army Institute of Surgical Research - 2012.
6. A.N.Konovalov, L.B.Lichtermann, AA.Potapov. Clinical guidelines of traumatic brain injury under red – Chapter 21. Battle injuries of skull and brain. М. Антидор, 2001 – P. 451 - 474.